

# Intrathoracic Osteolipoma

## Intrathoracic Osteolipoma

Leyla Nesrin Acar<sup>1</sup>, Erkmen Gülhan<sup>1</sup>, Pınar Bıçakçioğlu<sup>1</sup>, Arzu Ertürk<sup>2</sup>, Funda Demirağ<sup>3</sup>

<sup>1</sup>Department of Thoracic Surgery

<sup>2</sup>Department of Chest Diseases

<sup>3</sup>Department of Pathology, Atatürk Chest Diseases and Thoracic Surgery Research and Training Hospital, Ankara, Turkey

It was presented as an electronic poster (EP-168) at the 35th National Congress of the Turkish Respiratory Research Society (2-6 October 2013).

### Abstract

Lipomas are the most common benign soft tissue tumors. Although lipomas often appear in subcutaneous locations, they may develop in any part of the body. Intrathoracic osteolipomas and the malignant degeneration of osteolipomas are very rare. However, surgical resection is required for the diagnosis and treatment of lipomas. Complete resection is the only definitive treatment and the only way of preventing relapse. In this paper, we present a literature review and a rare intrathoracic osteolipoma case for which we performed a surgical resection.

### Keywords

Osteolipoma; Intrathoracic Lipoma; Surgery

DOI:10.4328/ECAM43

Received : 03.12.2014

Accepted : 24.01.2015

Published Online : 24.01.2015

Printed Online : 24.01.2015

Eu Clin Anal Med 2015;3(1): 10-2

**Corresponding Author:** Leyla Nesrin Acar, Department of Thoracic Surgery, Atatürk Chest Diseases and Thoracic Surgery Research and Training Hospital, 06280, Keçiören, Ankara, Turkey.  
P: +90 312 567 70 00/72 56 - F: +90 312 355 21 35 - E-Mail: acar8106@gmail.com

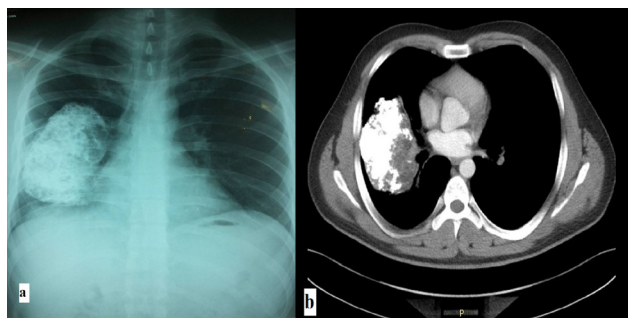
**How to cite this article:** Leyla Nesrin Acar, Erkmen Gulhan, Pinar Bicakcioglu, Arzu Erturk, Funda Demirag. Intrathoracic osteolipoma. Eu Clin Anal Med 2015;3(1): 10-2.

## Introduction

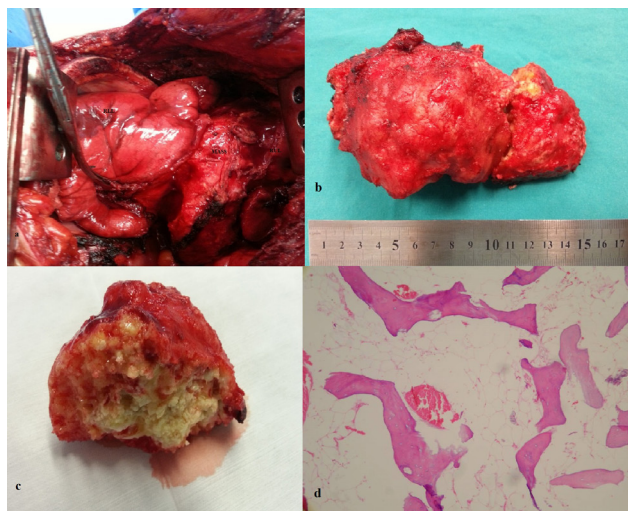
Lipomas are the most common benign soft tissue tumors. Although lipomas often appear in subcutaneous locations, they may develop in any part of the body. Intrathoracic lipomas are rare lesions that Fothergill first described in 1783. Intrathoracic osteolipomas are very rare [1-3]. The literature we reviewed included a few reports of intrathoracic osteolipoma cases. In this paper, we present a literature review and a rare intrathoracic osteolipoma case for which we performed a surgical resection.

## Case Report

A 30-year-old male patient without any active complaint underwent amputation above his right knee 16 years ago after a diagnosis of osteosarcoma. He did not receive postoperative chemotherapy or radiotherapy. During his follow-up visit, a mass showing progression on the right hemithorax, which appeared to be comparable to calcification within itself, was detected in his posteroanterior chest radiography (Figure 1a). Chest computed tomography (CT) showed a mass lesion with irregular margins containing widespread calcifications of 104x80x103mm extending posteriorly to the perihilar area of the right upper lobe (Figure 1b). Positron emission tomography (PET-CT) detected a mass with pleural-based widespread calcifications of 71x151mm with low-SUV involvement beginning at the right lung's upper lobe posterior segment and extending to the middle lobe, he was then referred to our hospital for diagnosis and treatment. Physical examination of the patient showed that his right leg was amputated above the knee and he had diminished breathing sounds in the right hemithorax. His routine hemogram biochemical tests were normal. The mass contained calci-



**Figure 1.** PA chest x-ray: Mass containing calcification in the right hemithorax(a), Chest CT: Mass containing calcification extending to the right perihilar area in the mediastinal window(b).



**Figure 2.** Intraoperative view of the mass(a); the excised mass(b); macroscopic view of the mass(c); microscopic view of the mass(d); lamellae consisting of bone spicules located in the fat tissue (HEX200).

fied sections, so it was not deemed appropriate to perform a trans-thoracic needle aspiration biopsy. A right posterolateral thoracotomy was performed on the patient for diagnostic and therapeutic purposes. During exploration, a well-circumscribed, encapsulated, solid mass was observed; this mass was located in a major fissure, compressed on the lower lobe, filled about one-third of the right hemithorax and did not show invasion to the surrounding tissue (Figure 2a). The mass was hard, so a frozen section could not be performed. The mass was completely excised, and lymph node sampling was performed. Macroscopy of the resected mass showed a cross-section with a hard consistency, which was partly consistent with fat tissue (Figure 2b,c). During the histopathological examination, benign lamellar bone spicules embedded in mature fat tissue were observed (Figure 2d). In line with these histopathological findings, the mass was reported to be osteolipoma. Lymph nodes 4 and 7 had a reactive, anthracotic appearance. Our patient was discharged on postoperative day 7 with no problems. The patient had no active complaints at his one-year follow-up visit, and no recurrence was detected.

## Discussion

Lipomas are benign mesenchymal tumors [1]. Heuer divided thoracic lipomas into three groups: 1-Dumbbell tumors, which are lesions with part of the intrathoracic mass linked to the mass in the extrathoracic region; 2-Lesions directly extending from the neck to the anterior superior mediastinum; and 3-Purely intrathoracic lesions, which have no link with any bone tissue [4]. Our case belongs to the third group.

Intrathoracic lipomas develop from submesothelial adipose tissue in the parietal pleura, diaphragm, mediastinum and extrapericardial area [5]. Histologically, lipomas are composed of mature fat cells. However, they may also contain mesenchymal elements, including bone, cartilage, smooth muscle or fibrous tissue. Depending on which elements are found, lipomas are referred to as osteolipomas, chondrolipomas, myelolipomas, fibrolipomas or angiolipomas. Osteolipomas contain mature bone spicules and are rare histologic variants of lipomas [6,7]. The pathogenesis of osteolipoma is unclear; however, two theories have been suggested. In the first theory, multipotent mesenchymal cells are considered similar to osteolipomas. In the second theory, repetitive trauma, metabolic changes or ischemia are thought to lead to the metaplasia of fibrous elements contained in lipomas and the development of osteoblasts [6].

Lipomas are encapsulated, and they grow slowly. Therefore, they usually do not lead to symptoms. Symptoms vary depending on location and size of the mass. They may compress on the bronchial system, oesophagus, vagus nerve, phrenic nerve or other tissues within the thorax. Accordingly, symptoms such as shortness of breath, dry cough, orthopnea, dysphagia, chest pain and cardiac arrhythmia may occur [1,3]. Jack et al. reported a case of left ventricular dysfunction that developed due to compression from an intrathoracic extrapericardial lipoma. The patient refused to have an operation so cardiac arrest developed because of compression from the mass [8]. Our patient did not have any active complaints. Lipomas can reach enormous sizes because they grow slowly. Yang et al. presented a case of the largest intrathoracic osteolipoma in the literature, which measured 26X19X12cm and was accidentally detected when the patient presented with complaints of dry cough and chest pain [3]. The mass we excised measured 8x16cm.

Intrathoracic lipomas are asymptomatic, so they are usually detected incidentally in a posteroanterior chest radiograph. CT and magnetic resonance imaging (MRI) are used to make a diagnosis [1,5]. Our patient had a history of above-knee amputation due to osteosarcoma, so he was followed using chest CT. Upon the detection of a growth in mass

during his follow-up visit, he was referred to our hospital for diagnosis and treatment.

The malignant degeneration of osteolipomas is very rare. Surgical resection is required for the diagnosis and treatment of lipomas. Complete resection is the only definitive treatment and the only way of preventing relapse [1,3]. Accordingly, we performed a complete resection on the intrathoracic mass and treated it. Local recurrence is very rare in resected intrathoracic lipomas [1,3,6]. The patient had no active complaints at his one-year follow-up visit, and no recurrence was detected.

In conclusion, osteolipomas are lipomas containing mature bone tissue. They show slow growth without any symptoms. Complete surgical resection is the only treatment. Intrathoracic osteolipomas are rare benign lesions. Only a few cases have been reported worldwide as occurring in this location, and none have been reported in the Turkish literature. The aim of this paper is to report on the first intrathoracic osteolipoma in Turkish literature, according to our knowledge, and to review clinical features of the treatment.

#### Scientific Responsibility Statement

The authors declare that they are responsible for the article's scientific content including study design, data collection, analysis and interpretation, writing, some of the main line, or all of the preparation and scientific review of the contents and approval of the final version of the article.

#### Animal and human rights statement

All procedures performed in this study were in accordance with the ethical standards of the institutional and/or national research committee and with the 1964 Helsinki declaration and its later amendments or comparable ethical standards. No animal or human studies were carried out by the authors for this article.

**Funding:** None

#### Conflict of interest

None of the authors received any type of financial support that could be considered potential conflict of interest regarding the manuscript or its submission.

#### References

1. Chen M, Yang J, Zhu L, Zhao H. Intrathoracic giant pleural lipoma: case report and review of the literature. *J Cardiothoracic Surg* 2013;8(1):196.
2. Sulzer MA, Goei R, Bollen EC, Theunissen PH, Maesen FP. Lipoma of the external thoracic wall. *Eur Respir J* 1994;7(1):207-9.
3. Yang J, Li S, Kang A, Chen X, Su B, Jin Y. A giant intrathoracic osteolipoma: A case report and review of the literature. *Int J Surg Case Rep* 2012;3(7):290-2.
4. Heuer GJ. The thoracic lipomas. *Ann Surg* 1933;98(5):801-19.
5. Gaerte SC, Meyer CA, Winer-Muram HT, Tarver RD, Conces DJ Jr. Fat-containing lesions of the chest. *Radiographics* 2002;22(1):61-78.
6. Demiralp B, Alderete JF, Kose O, Ozcan A, Cicek I, Basbozkurt M. Osteolipoma independent of bone tissue: a case report. *Cases J* 2009;2:8711.
7. Saghafi S, Mellati E, Sohrabi M, Raahpeyma A, Salehinejad J, Zare-Mahmoodabadi R. Osteolipoma of the oral and pharyngeal region: report of a case and review of the literature. *Oral Surg Oral Med Oral Pathol Oral Radiol Endod* 2008;105(6):e30-4.
8. Jack AI, Blohm ME, Lye M. An intrathoracic lipoma impairing left ventricular function. *Br Heart J* 1995;74(1):95.